

# ARE CHANGES IN SPINOPELVIC PARAMETERS EXPECTED AFTER PROLONGED HALO GRAVITY TRACTION FOR THE TREATMENT OF SEVERE SPINAL DEFORMITIES?

SÃO ESPERADAS ALTERAÇÕES NOS PARÂMETROS ESPINOPÉLVICOS APÓS TRAÇÃO HALO-GRAVITACIONAL PROLONGADA NO TRATAMENTO DE DEFORMIDADES GRAVES DA COLUNA?

¿SE ESPERAN CAMBIOS EN LOS PARÁMETROS ESPINOPÉLVICOS TRAS UNA TRACCIÓN HALO-GRAVITACIONAL PROLONGADA EN EL TRATAMIENTO DE DEFORMIDADES GRAVES DE LA COLUMNA?

GIANCARLO JORIO ALMEIDA<sup>1</sup> , ALDERICO GIRÃO CAMPOS DE BARROS<sup>1</sup> , GABRIEL FARIAS ALVES<sup>1</sup> , ANA CAROLINA LEAL<sup>2</sup> , LUÍS E. CARELLI<sup>1</sup> 

1. Instituto Nacional de Traumatologia e Ortopedia (INTO), Department of Spine Surgery, São Paulo, SP, Brazil.

2. Instituto Nacional de Traumatologia e Ortopedia (INTO), Teaching and Research Division, São Paulo, SP, Brazil.

## ABSTRACT

**Objective:** To evaluate whether prolonged preoperative halo gravity traction (HGT) influences spinopelvic parameters in patients with severe spinal deformities. **Methods:** This retrospective observational study included patients treated with preoperative HGT between 2017 and 2023 at a spine deformity referral center. Inclusion criteria comprised curves  $>100^\circ$ , and a minimum of two weeks of preoperative traction. Pre- and post-HGT radiographs were analyzed to assess changes in coronal and sagittal Cobb angles, sagittal vertical axis (SVA), and spinopelvic parameters—pelvic incidence (PI), pelvic tilt (PT), sacral slope (SS), and lumbar lordosis (LL). Statistical significance was set at  $p \leq 0.05$ . **Results:** Fifteen patients met the inclusion criteria. HGT resulted in significant preoperative reductions in proximal thoracic, main thoracic, and thoracolumbar/lumbar Cobb angles. Sagittal Cobb angle and T5–T12 kyphosis significantly improved, while T2–T5 kyphosis remained unchanged. Spinopelvic parameters (PI, PT, SS, LL) and SVA did not show statistically significant changes after HGT. Individual LL variations were noted, but not at the group level. **Conclusion:** While HGT remains an important tool for the management of severe spinal deformities, its influence on spinopelvic parameters is negligible. **Level of Evidence IV; Therapeutic Study.**

**Keywords:** Scoliosis; Kyphosis; Traction; Spine; Radiography, Panoramic.

## RESUMO

**Objetivo:** Avaliar se a tração halo-gravitacional (HGT) pré-operatória prolongada influencia os parâmetros espinopélvicos em pacientes com deformidades graves da coluna vertebral. **Métodos:** Estudo observacional retrospectivo com pacientes tratados com HGT pré-operatória entre 2017 e 2023 em um centro de referência para deformidades da coluna. Os critérios de inclusão foram curvas  $>100^\circ$  e pelo menos duas semanas de tração pré-operatória. Radiografias antes e após a HGT foram analisadas para avaliar alterações nos ângulos de Cobb (coronal e sagital), no alinhamento vertical sagital (SVA) e nos parâmetros espinopélvicos – incidência pélvica (PI), inclinação pélvica (PT), inclinação sacral (SS) e lordose lombar (LL). O nível de significância estatística foi  $p \leq 0,05$ . **Resultados:** Quinze pacientes atenderam aos critérios de inclusão. A HGT promoveu reduções pré-operatórias significativas nos ângulos de Cobb torácico proximal, torácico principal e toracolumbar/lombar. O ângulo de Cobb sagital e a cifose entre T5–T12 melhoraram significativamente, enquanto a cifose entre T2–T5 permaneceu inalterada. Os parâmetros espinopélvicos (PI, PT, SS, LL) e o SVA não apresentaram alterações estatisticamente significativas após a HGT. Foram observadas variações individuais na LL, mas não em nível grupal. **Conclusão:** Embora a HGT permaneça uma ferramenta importante no manejo de deformidades graves da coluna, sua influência sobre os parâmetros espinopélvicos é mínima. **Nível de Evidência IV; Estudo Terapêutico.**

**Descritores:** Escoliose; Cifose; Tração; Coluna Vertebral; Radiografia Panorâmica.

## RESUMEN

**Objetivo:** Evaluar si la tracción halo-gravitacional (HGT) preoperatoria prolongada influye en los parámetros espinopélvicos en pacientes con deformidades graves de la columna. **Métodos:** Estudio observacional retrospectivo que incluyó pacientes tratados con HGT preoperatoria entre 2017 y 2023 en un centro de referencia para deformidades espinales. Los criterios de inclusión fueron curvas  $>100^\circ$  y al menos dos semanas de tracción preoperatoria. Se analizaron radiografías pre y post-HGT para evaluar cambios en los ángulos de Cobb coronal y sagital, el alineamiento vertical sagital (SVA) y los parámetros espinopélvicos – incidencia pélvica (PI), inclinación pélvica (PT), pendiente sacra (SS) y lordosis lumbar (LL). Se consideró estadísticamente significativo  $p \leq 0.05$ .

Study conducted by the Instituto Nacional de Traumatologia e Ortopedia Jamil Haddad, Av. Brasil, 500, Caju, Rio de Janeiro, RJ, Brazil. 20940-070.

Correspondence: Giancarlo Jorio Almeida. 94, Rua Raul Pompeia, apto 705, Copacabana, Rio de Janeiro, RJ, Brazil. 22080002. gianjorioalmeida@gmail.com



**Resultados:** Quince pacientes cumplieron los criterios de inclusión. La HGT resultó en reducciones significativas preoperatorias en los ángulos de Cobb torácico proximal, torácico principal y toracolumbar/lumbar. El ángulo sagital de Cobb y la cifosis T5–T12 mejoraron significativamente, mientras que la cifosis T2–T5 no mostró cambios. Los parámetros espinopélvicos (PI, PT, SS, LL) y el SVA no presentaron cambios estadísticamente significativos tras la HGT. Se observaron variaciones individuales en la LL, pero no a nivel grupal. **Conclusión:** Aunque la HGT sigue siendo una herramienta importante para el manejo de deformidades graves de la columna, su influencia sobre los parámetros espinopélvicos es mínima. **Nivel de Evidencia IV; Estudio Terapéutico.**

**Descriptores:** Escoliose; Cifosis; Tracción; Columna Vertebral; Radiografía Panorámica.

## INTRODUCTION

Sagittal spine alignment relies on four interrelated curvatures that maintain posture and balance, and any disruption can trigger compensatory mechanisms involving musculature, sacral position, and lower limb adjustments.<sup>1</sup>

The study of sagittal alignment parameters in scoliosis is relatively recent, and much remains unknown. In 2018, Abelin-Genevois et al.<sup>2</sup> classified Adolescent Idiopathic Scoliosis (AIS) based on sagittal angles, describing different types according to thoracic kyphosis: (1) Normal Kyphosis, (2a) Hypokyphosis, (2b) Hypokyphosis with Thoracolumbar Kyphosis, and (3) Cervicothoracic Kyphosis. Their study also identified significant correlations between thoracic kyphosis, lumbar lordosis (LL), C7 slope, and cervical lordosis.<sup>2</sup>

In the sagittal plane, Pelvic Tilt (PT) is a key measurement, as increased PT in the general population is associated with higher energy expenditure during walking.<sup>1</sup> In idiopathic scoliosis, elevated PT has also been linked to impaired gait, characterized by a greater swing phase and reduced stance phase.<sup>3</sup> In AIS, preoperative spinopelvic parameters generally remain unchanged after surgery, with thoracic kyphosis being the only parameter that tends to improve postoperatively.<sup>4</sup>

Halo gravity traction (HGT) is widely utilized for preoperative treatment of severe spinal deformities, with clear benefits in clinical symptoms and surgical planning. Radiographically, the improvement of coronal Cobb angle values is well-documented, reinforcing its effectiveness in reducing the curve's severity.<sup>5</sup>

HGT is a technique that applies controlled, gradual traction to the spine using a cranial halo fixed to the skull via pins. The traction force is progressively increased, allowing for slow and controlled correction of the spinal deformity.<sup>5</sup> This method has been shown to improve surgical outcomes by reducing the rigidity of the curve, thereby decreasing the need for aggressive osteotomies.<sup>6–8</sup> The process also provides time for patients to undergo preoperative physiotherapy and nutritional optimization, which can enhance pulmonary function and overall tolerance to surgical intervention.<sup>7</sup> Traction can be performed in a hospital setting using a specialized traction bed, a wheelchair-based traction system, or a combination of both, offering patients relative mobility and improved quality of life during the preoperative period.<sup>9</sup>

Despite these benefits, most studies on HGT focus primarily on coronal deformity correction, typically assessed by the Cobb angle. This study is among the first to evaluate whether the benefits of HGT extend to sagittal vertebral alignment and spinopelvic parameters.

## METHODS

To test the hypothesis that HGT could influence sagittal parameters before definitive surgery, we conducted an observational, retrospective study analyzing medical records and radiographic images of patients with severe spinal deformities who underwent preoperative HGT in a single referral center for spinal deformity surgery of the Brazilian public healthcare system.

This study was approved by the local ethics committee (CAAE 71146723.6.0000.5273), and patients or their legal guardians provided consent for the anonymized use of their images. All patients treated with HGT between 2017 and 2023 were included if their Cobb angles exceeded 100 degrees. Patients with less severe deformities, those who received intraoperative traction only, or those who underwent less than two weeks of traction were excluded.

Radiographic measurements were taken before and after HGT, evaluating sagittal Cobb angles, sagittal vertical axis (SVA), and spinopelvic parameters (PI, PT, and SS), following the Scoliosis Research Society's Radiographic Measurement Manual.<sup>10</sup> Data collection and analysis were performed using Surgimap software.

The traction protocol followed in our institution involved the application of a cranial halo under sedation, using four to six pins, secured at a standard torque based on cranial bone density. Initial traction was set at approximately 5 kg and was gradually increased by 1 kg per day, depending on patient tolerance, until reaching a maximum of 50% of body weight. Throughout the HGT period, patients alternated between different traction positions, including bed traction, wheelchair traction, and assisted standing. A multidisciplinary team monitored the patients daily, ensuring proper pin care, neurological assessments, and symptom management. Patients were kept under maximum traction weight until there was no further improvement in the deformity. At this point, definitive instrumentation, osteotomy, and arthrodesis surgery were scheduled.

Statistical analysis was conducted using GraphPad Prism 8. The normality of the data was assessed using the Kolmogorov-Smirnov test. Paired T-tests or Wilcoxon tests were used to compare pre- and post-HGT values, with statistical significance set at  $p \leq 0.05$ .

## RESULTS

From 2017 to 2023, 15 patients met the inclusion criteria. The cohort had an average age of 16.9 years, with skeletal maturity ranging from Risser 0 to Risser 5, distributed as follows: two Risser 0 patients (13.3%), one Risser 2 patient (6.6%), two Risser 3 patients (13.3%), one Risser 4 patient (6.6%), and nine Risser 5 patients (60%). The individual patients' data are presented in Table 1. All patients in the study underwent HGT preoperative treatment until no further improvement in the deformity was observed. There were no significant complications necessitating the discontinuation of HGT.

A statistically significant reduction in the proximal thoracic Cobb angle ( $p = 0.02$ ), main thoracic Cobb angle ( $p < 0.0001$ ), and thoracolumbar/lumbar Cobb angle ( $p = 0.0064$ ) was observed after HGT. The overall sagittal Cobb angle showed a significant mean reduction of 19.9 degrees ( $p = 0.0003$ ), while T5-T12 kyphosis improved by 15.6 degrees ( $p = 0.01$ ). However, no significant changes were found in spinopelvic parameters, with pelvic tilt showing an average change of 3.1 degrees ( $p = 0.42$ ), pelvic incidence a difference of only 0.5 degrees ( $p = 0.32$ ), sacral slope a change of 0.9 degrees ( $p = 0.72$ ), and lumbar lordosis a variation of 6.5 degrees ( $p = 0.20$ ). While lumbar lordosis did not change significantly at the group level, individual variations were observed. Additionally, sagittal vertebral axis (SVA) showed a non-significant increase of 3.9 mm ( $p = 0.45$ ). The T2-T5 kyphosis remained unchanged ( $p > 0.999$ ). Table 2 presents more details about the statistics. Two illustrative cases from the study are presented in Figure 1 and Figure 2. While these patients present with different clinical pathologies, in both cases, there was no improvement in the sagittal parameters.

## DISCUSSION

The majority of studies on preoperative HGT focus on the reduction of Cobb angles, a finding corroborated by our study.<sup>8,11</sup> However, our aim was to investigate whether HGT influences sagittal parameters beyond coronal plane correction.

**Table 1.** All patients in the study, along with their demographic data and radiographical measurements. Age (years old). HGT: Halo gravity Traction. PT: Pelvic Tilt. SS: Sacral Slope. PI: Pelvic Incidence; LL: Lumbar Lordosis. SVA: Sagittal Vertebral Axis.

| Patient | Diagnosis             | Sex | Age (yo) | Risser | HGT Time (days) | Initial Cobb | Post HGT Cobb | Initial Sagittal Cobb | Post HGT Sagittal Cobb | Pre HGT PT | Post HGT PT | Pre HGT SS | Post HGT SS | Pre HGT PI | Post HGT PI | Pre HGT LL | Post HGT LL | Pre HGT SVA | Post HGT SVA | Pre HGT PI-LL | Post HGT PI-LL |
|---------|-----------------------|-----|----------|--------|-----------------|--------------|---------------|-----------------------|------------------------|------------|-------------|------------|-------------|------------|-------------|------------|-------------|-------------|--------------|---------------|----------------|
| 1       | Adolescent Idiopathic | M   | 32       | 5      | 30              | 165.7        | 89.6          | 148.4                 | 126.3                  | 18.9       | 32.7        | 24.2       | 22.8        | 43.1       | 55.6        | 101.3      | 94.4        | 24.3        | 26.9         | -58.2         | -38.8          |
| 2       | Congenital            | M   | 11       | 0      | 54              | 17           | 12.7          | 115.2                 | 89                     | 6.8        | 6           | 32.7       | 34.4        | 39.5       | 40.4        | 32.7       | 54.8        | 227.7       | 90.4         | 6.8           | -14.4          |
| 3       | Adolescent Idiopathic | F   | 18       | 5      | 54              | 127.7        | 108.9         | 99.2                  | 92.8                   | -5.4       | -7.8        | 43.5       | 43.7        | 38         | 38          | 70         | 67.4        | 17          | 21.7         | -32           | -29.4          |
| 4       | Adolescent Idiopathic | F   | 13       | 4      | 42              | 143.3        | 130.6         | 73.6                  | 53.2                   | 11.5       | 6           | 32.9       | 33.3        | 44.4       | 39.2        | 82.7       | 100.5       | -8.6        | -6.9         | -38.3         | -61.3          |
| 5       | Adolescent Idiopathic | F   | 17       | 5      | 95              | 148.3        | 70.9          | 101.2                 | 92.3                   | 32         | 5.6         | 25.1       | 46.5        | 57.1       | 52.1        | 101.9      | 89.9        | 52.1        | 73.7         | -44.8         | -37.8          |
| 6       | Neuromuscular         | M   | 9        | 0      | 27              | 106.5        | 94.9          | 80.6                  | 53                     | 18.4       | 14.4        | 24         | 34.6        | 42.3       | 49          | 63.5       | 63          | 53.4        | 155.1        | -21.2         | -14            |
| 7       | Adolescent Idiopathic | M   | 11       | 2      | 30              | 127.5        | 99.2          | 119.4                 | 86.3                   | 29.4       | 3.5         | 40.9       | 21.8        | 70.4       | 154.7       | 111.1      | 49.1        | 49.9        | 96.1         | -40.7         | 105.6          |
| 8       | Adolescent Idiopathic | M   | 20       | 5      | 28              | 129.2        | 104.4         | 92.8                  | 104.7                  | 7.8        | 1.8         | 37.4       | 29.5        | 134.8      | 31.3        | 63.4       | 58.8        | 8.2         | -25          | 71.4          | -27.5          |
| 9       | Congenital            | F   | 29       | 5      | 23              | 132.7        | 131.1         | 125.8                 | 120.4                  | 16.1       | 1.8         | 40.2       | 33.3        | 24.2       | 31.5        | 69.8       | 53.3        | -39.9       | -20          | -45.6         | -21.8          |
| 10      | Adolescent Idiopathic | M   | 19       | 5      | 14              | 148.6        | 127.6         | 123.7                 | 103.1                  | 2.9        | 6.3         | 37.9       | 35          | 34.9       | 41.3        | 71.1       | 102.4       | -11.8       | 2            | -36.2         | -61.1          |
| 11      | Syndromic             | M   | 11       | 3      | 30              | 132.2        | 111.1         | 84.3                  | 30.5                   | -6.2       | -17         | 30.6       | 40.8        | 24.3       | 23.7        | 90.3       | 62.6        | 32.7        | -16.1        | -66           | -38.9          |
| 12      | Adolescent Idiopathic | F   | 20       | 5      | 55              | 131.5        | 88.5          | 55.9                  | 39.3                   | 6.4        | 5.4         | 37.5       | 39.1        | 43.8       | 44.5        | 77         | 63.1        | 14.8        | 30.3         | -33.2         | -18.6          |
| 13      | Adolescent Idiopathic | F   | 15       | 5      | 30              | 125.5        | 105.7         | 70.3                  | 54.9                   | -0.1       | 7.4         | 38.7       | 27.7        | 38.6       | 35.1        | 67.9       | 50.5        | 19.5        | -3.1         | -29.3         | -15.4          |
| 14      | Adolescent Idiopathic | F   | 18       | 5      | 36              | 117.9        | 86.5          | 70.3                  | 61.4                   | 2.7        | 7.4         | 26.1       | 39.4        | 28.7       | 32          | 86.5       | 84.4        | -53.1       | 13.7         | -57.8         | -52.4          |
| 15      | Congenital            | F   | 10       | 3      | 38              | 120.9        | 88.1          | 79.1                  | 46.7                   | 6.1        | 5.2         | 38         | 42.1        | 44.1       | 47.3        | 67.3       | 64.3        | 102         | 108          | -23.2         | -17            |
|         | Average:              |     | 16.9     |        | 39.1            | 125.0        | 96.7          | 96.0                  | 76.9                   | 9.82       | 5.25        | 33.98      | 34.93       | 47.21      | 47.71       | 77.10      | 70.57       | 32.55       | 36.45        | -29.89        | -22.85         |

**Table 2.** Results of statistical analysis comparing coronal and sagittal values before and after HGT. <sup>a</sup>Paired T-test; <sup>b</sup>Wilcoxon test. There were no statistically significant changes in Spinopelvic Parameters.

| Parameters                | Pre HGT      | Post HGT    | P value   |
|---------------------------|--------------|-------------|-----------|
| Proximal Thoracic Cobb    | 59.0 ± 20.2  | 51.3 ± 21.5 | 0.02 a    |
| Main Thoracic Cobb        | 124.6 ± 34.4 | 93.4 ± 33.5 | <0.0001 b |
| Thoracolumbar Lumbar Cobb | 53.0 ± 36.6  | 37.9 ± 24.4 | 0.0064 a  |
| SVA                       | 32.5 ± 66.6  | 36.4 ± 55.0 | 0.45 b    |
| T2T5                      | 12.5 ± 28.0  | 12.5 ± 24.8 | >0.999 a  |
| T5T12                     | 95.4 ± 24.5  | 79.8 ± 21.6 | 0.01 a    |
| Sagittal Cobb             | 95.9 ± 26    | 76 ± 30.3   | 0.0003 a  |
| PT                        | 10.6 ± 10.5  | 7.5 ± 8.8   | 0.42 b    |
| PI                        | 47.2 ± 27.0  | 47.7 ± 30.9 | 0.32 b    |
| SS                        | 34.0 ± 6.5   | 34.9 ± 7.2  | 0.72 a    |
| LL                        | 77.1 ± 19.5  | 70.6 ± 18.5 | 0.20 b    |

Our results indicate that while HGT contributes to improved sagittal Cobb angles, it does not significantly alter spinopelvic parameters or sagittal vertebral axis. This suggests that sagittal correction via HGT is limited, and alternative strategies may be necessary to achieve comprehensive sagittal balance.

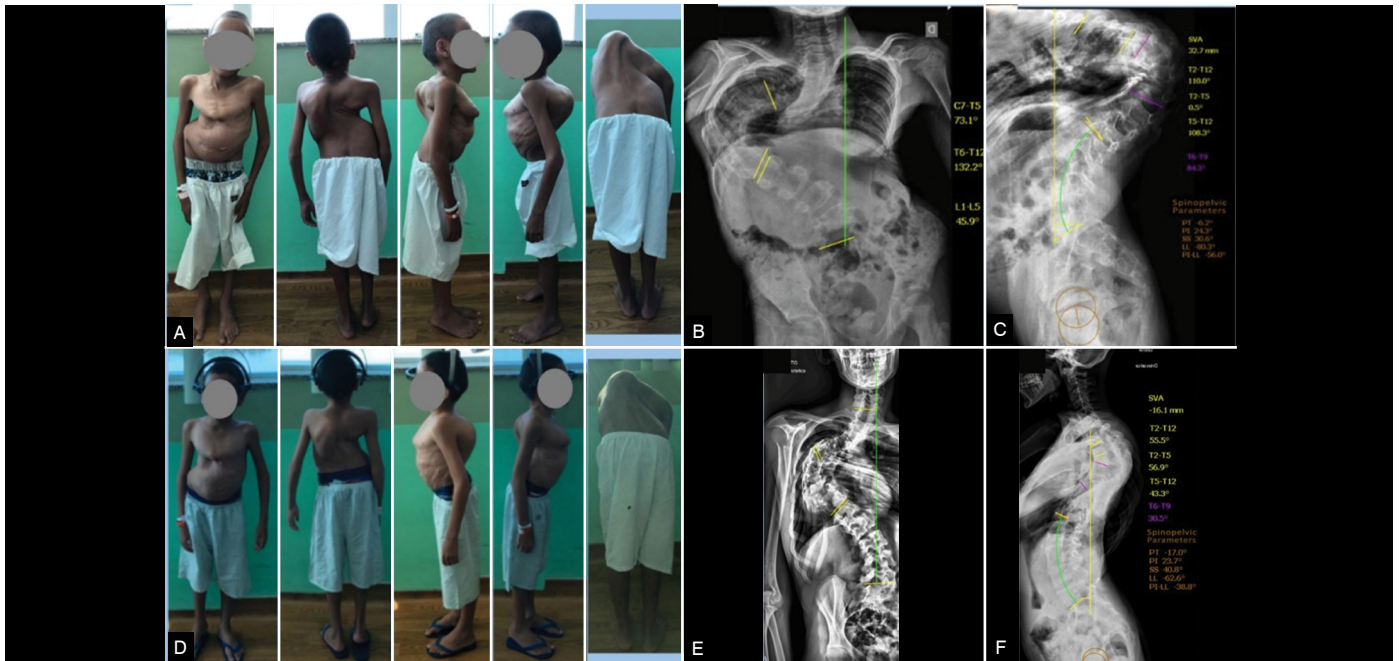
Pinto et al. (2019) demonstrated that sagittal balance in adolescent idiopathic scoliosis is strongly correlated with cervical morphology and upper thoracic kyphosis (T1-T5). In contrast, lumbar lordosis (LL) is more associated with lower thoracic curvature (T5-T12) and influenced by pelvic parameters such as pelvic incidence (PI) and sacral slope (SS).<sup>12</sup> These findings are particularly relevant to our study population, as severe deformities often result in compensatory patterns involving the interaction between the cervical, thoracic segments, and pelvis.

In patients with thoracic AIS, pelvic retroversion plays a crucial role in postural adaptation, a mechanism that helps maintain sagittal balance. The preservation of lower lumbar mobility in the planning of spinal scoliosis surgery proves to be important to reduce strain on the lumbar spine and to improve postural adaptability.<sup>13</sup> Another finding in the literature is that in thoracic AIS, particularly in hypokyphotic patients, an overcorrection of lumbar lordosis could induce a posterior shift of the fusion mass that ultimately leads to an increased risk of proximal junctional kyphosis.<sup>14,15</sup>

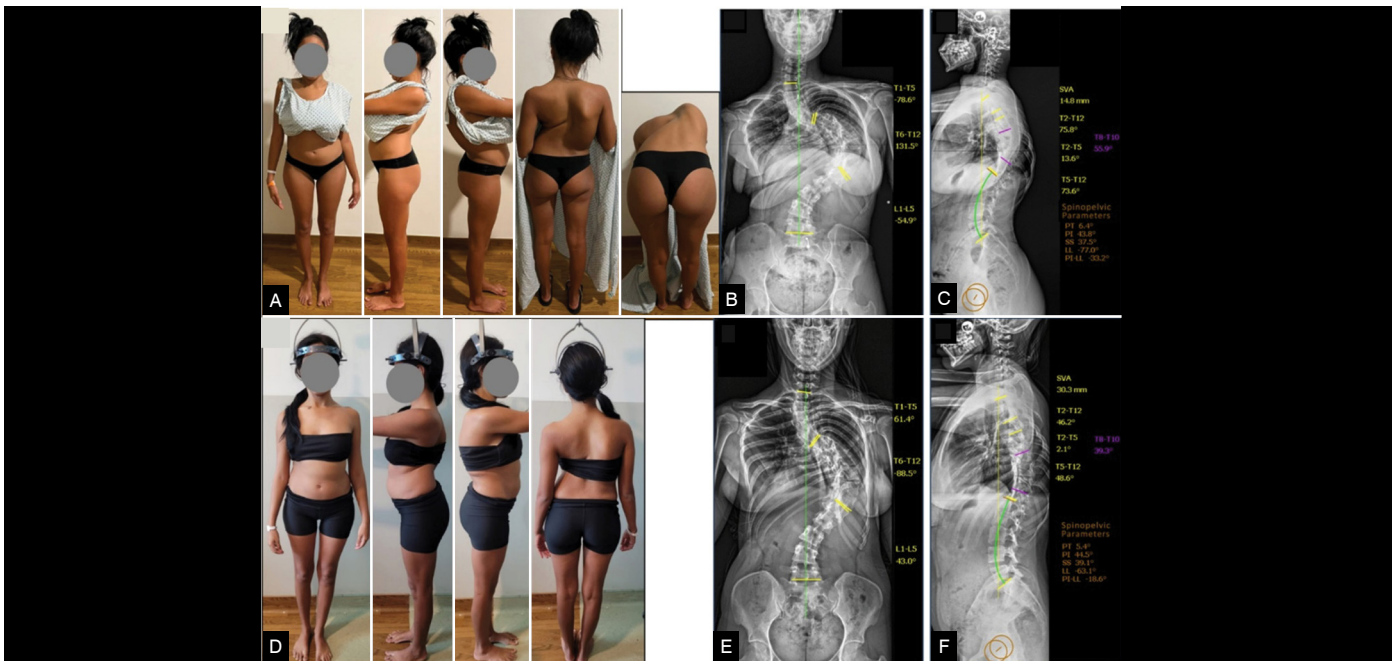
In severe and rigid curves, patients with smaller PI and sagittal vertical axis (SVA) are more likely to present with sagittal imbalance. Zhang et al. did find that a PI of < 39 degrees and a PI-LL mismatch are major factors in sagittal imbalance persistence.<sup>16</sup> Since PI is an intrinsic, non-modifiable parameter, we anticipated that preoperative HGT could influence lumbar lordosis; however, our findings did not support this hypothesis.

The surgical management of severe and rigid spinal deformities is complex and often requires a multidisciplinary approach. Preoperative HGT remains a valuable tool for reducing deformity severity and potentially minimizing the need for extensive osteotomies.<sup>5</sup>

Despite its limitations in modifying sagittal parameters, HGT provides other preoperative benefits, including a gradual adaptation of the spinal cord to correction forces, reduced neurological risks, and an opportunity for medical optimization.<sup>9</sup> The ability to achieve partial correction before definitive surgery allows surgeons to plan less invasive approaches in certain cases.<sup>11</sup> Moreover, patient adherence to prolonged HGT is generally good, with minimal reported complications.<sup>7</sup> Therefore, understanding both the benefits and limitations of HGT is essential for optimizing patient outcomes and ensuring that treatment strategies are tailored to the individual needs of each case.



**Figure 1.** A male 11-year-old patient with Prune Belly Syndrome was submitted to 30 days preoperative HGT. A. Preoperative clinical images. B. Coronal radiography Pre HGT. C. Sagittal radiography Pre HGT. D. Last preoperative clinical images. E. Last preoperative coronal radiography. F. Last preoperative sagittal radiography. Besides the important coronal improvement, there was no change in spinopelvic parameters. Source: Authors.



**Figure 2.** A 20-year-old female 20 years old patient with severe, rigid idiopathic adolescent scoliosis submitted to preoperative HGT for 55 days. A. Preoperative clinical images with Adams maneuver. B. Coronal radiography Pre-HGT. C. Sagittal radiography Pre-HGT. D. Last preoperative clinical images. E. Last preoperative coronal radiography. F. Last preoperative sagittal radiography. Besides the important coronal improvement, there was also no change in spinopelvic parameters. Source: Authors.

## CONCLUSION

While HGT remains an important tool for the management of severe spinal deformities, its influence on spinopelvic parameters is negligible.

All authors declare no potential conflict of interest related to this article.

**CONTRIBUTIONS OF THE AUTHORS:** Each author contributed individually and significantly to the development of this article. AJG: Conceptualization, formal analysis, research, and writing – original draft; BCAG: Curation, methodology, conceptualization, and writing –review and editing; AFG: Formal analysis, research, and writing – original draft; LAC: Curation and methodology. STLEC: Conceptualization, validation, visualization and writing – review and editing.

## REFERENCES

1. Menezes CM, Lacerda GC, Lamarca S. Sagittal Alignment Concepts and Spinopelvic Parameters. *Rev Bras Ortop* (Sao Paulo). 2022;58(1):1-8. doi: 10.1055/s-0042-1742602.
2. Abelin-Genevois K, Sassi D, Verdun S, Roussouly P. Sagittal classification in adolescent idiopathic scoliosis: original description and therapeutic implications. *Eur Spine J*. 2018;27(9):2192-2202. doi: 10.1007/s00586-018-5613-1.
3. Liu Y, Li X, Dou X, Huang Z, Wang J, Liao B, et al. Correlational analysis of three-dimensional spinopelvic parameters with standing balance and gait characteristics in adolescent idiopathic scoliosis: A preliminary research on Lenke V. *Front Bioeng Biotechnol*. 2022;10:1022376. doi: 10.3389/fbioe.2022.1022376.
4. Souza AFMD, Avila LM, Aguiar CAD, Rocha LEMD. PRE- AND POSTOPERATIVE COMPARATIVE ANALYSIS OF THE SPINOPELVIC AND GLOBAL SAGITTAL PARAMETERS OF PATIENTS WITH ADOLESCENT IDIOPATHIC SCOLIOSIS. *Coluna/Columna*. 2022;21(1):e250514. doi:10.1590/s1808-185120222101250514.
5. McIntosh AL, Ramo BS, Johnston CE. Halo Gravity Traction for Severe Pediatric Spinal Deformity: A Clinical Concepts Review. *Spine Deform*. 2019;7(3):395-403. doi: 10.1016/j.jspd.2018.09.068.
6. Rinella A, Lenke L, Whitaker C, Kim Y, Park SS, Peelle M, et al. Perioperative halo-gravity traction in the treatment of severe scoliosis and kyphosis. *Spine* (Phila Pa 1976). 2005;30(4):475-82. doi: 10.1097/01.brs.0000153707.80497.a2.
7. Cechin IE, Alves GF, Barros AGCD, Silva LECTD. Complications of prolonged halo-gravitational traction in spinal deformity surgeries. *Coluna/Columna*. 2023;22(1):e265394. doi: 10.1590/S1808-18512022201265394.
8. Koller H, Zenner J, Gajic V, Meier O, Ferraris L, Hitzl W. The impact of halo-gravity traction on curve rigidity and pulmonary function in the treatment of severe and rigid scoliosis and kyphoscoliosis: a clinical study and narrative review of the literature. *Eur Spine J*. 2012;21(3):514-29. doi: 10.1007/s00586-011-2046-5.
9. Sponseller PD, Takenaga RK, Newton P, Boachie O, Flynn J, Letko L, et al. The use of traction in the treatment of severe spinal deformity. *Spine*. 2008;33(21):2305-9. doi: 10.1097/BRS.0b013e318184ef79.
10. O'Brien MF, Kuklo TR, Blanke KM; Lenke LG. Spinal Deformity Study Group Radiographic Measurement Manual. Medtronic. [Internet]. 2008. Available at: <https://www.srs.org/Files/Research/Manuals-and-Publications/sdsg-radiographic-measurement-manual.pdf>.
11. Teixeira da Silva LE, de Barros AG, de Azevedo GB. Management of severe and rigid idiopathic scoliosis. *Eur J Orthop Surg Traumatol*. 2015;25 Suppl 1(Suppl 1):S7-12. doi: 10.1007/s00590-015-1650-1.
12. Pinto EM, Alves J, Teixeira A, Miranda A. SAGITTAL BALANCE IN ADOLESCENT IDIOPATHIC SCOLIOSIS. *Coluna/Columna*. 2019;18(3):182-186. doi: 10.1590/S1808-185120191803191004.
13. Zhu W, Liu Z, Sha S, Guo J, Bao H, Xu L, et al. Postoperative changes in sagittal spinopelvic alignment in sitting position in adolescents with idiopathic thoracic scoliosis treated with posterior fusion: an initial analysis. *J Neurosurg Pediatr*. 2018;22(1):74-80. doi: 10.3171/2018.2.PEDS17687.
14. Vidal C, Mazda K, Ilharreborde B. Sagittal spino-pelvic adjustment in severe Lenke 1 hypokyphotic adolescent idiopathic scoliosis patients. *Eur Spine J*. 2016;25(10):3162-3169. doi: 10.1007/s00586-016-4681-3.
15. Ilharreborde B. Sagittal balance and idiopathic scoliosis: does final sagittal alignment influence outcomes, degeneration rate or failure rate? *Eur Spine J*. 2018;27(Suppl 1):48-58. doi: 10.1007/s00586-018-5472-9.
16. Zhang Z, Wang L, Li JC, Liu LM, Song YM, Yang X. Characteristics of Sagittal Alignment in Patients with Severe and Rigid Scoliosis. *Orthop Surg*. 2023;15(6):1607-1616. doi: 10.1111/os.13749.